

# An Image of Hutch Diverticulum with Ureteric Insertion

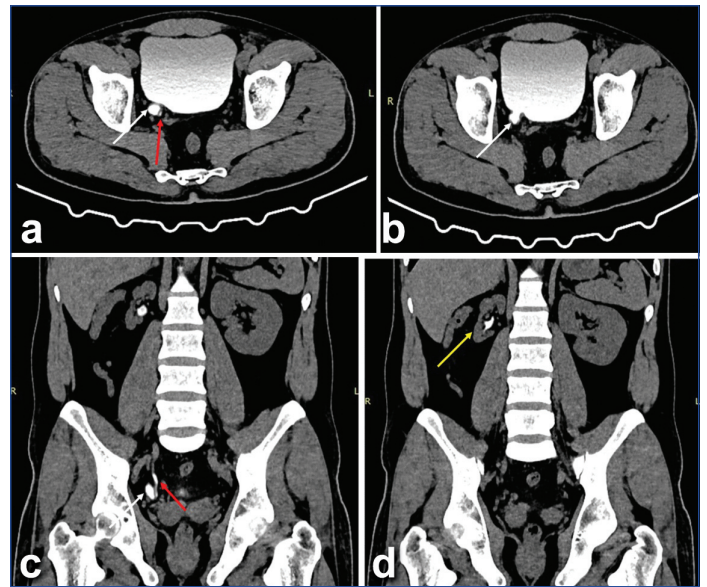
BANDARI KAAVYA<sup>1</sup>, SENTHIL KUMAR AIYAPPAN<sup>2</sup>, YESHWANTH RAJU NARAYANAN<sup>3</sup>, YATHAM RAMA RAO<sup>4</sup>

**Keywords:** Cortical scars, Haematuria, Micturating cystourethrogram, Vesicoureteric reflux

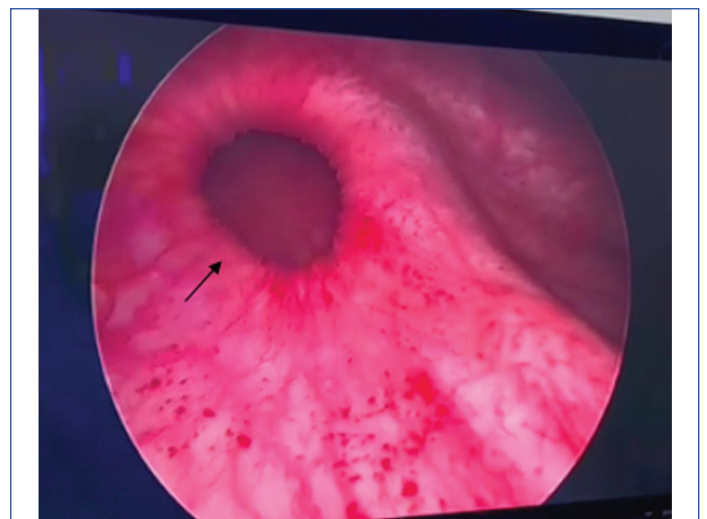
A 38-year-old male patient presented with complaints of occasional right loin pain, dysuria, and suprapubic tenderness for three weeks. The patient had no history of haematuria. Upon examination, the patient was afebrile, and vitals were stable. Blood tests revealed mild neutrophilic leukocytosis, and urine tests revealed a few pus cells. Further radiological investigations were conducted. An initial ultrasound performed outside, one week earlier, showed a small-sized right kidney measuring 8 cm with cortical scars, raised cortical echoes, and ill-defined corticomedullary differentiation. A small outpouching was noted in the posterior wall of the urinary bladder, suggestive of a diverticulum. The patient underwent a Micturating Cystourethrogram (MCU) to rule out vesico-ureteric reflux. The MCU showed reflux of contrast from the bladder into the right ureter and pelvi-calyceal system without dilatation, suggestive of grade-II vesico-ureteric reflux on the right-side. However, the diverticulum could not be delineated on the MCU since it was small.

The urethra was normal with no evidence of urethral obstruction [Table/Fig-1a,b]. The patient then underwent a computed tomography scan immediately after the MCU, confirming a small-sized right kidney with cortical scarring [Table/Fig-2a-d]. Grade-II vesico-ureteric reflux was associated according to the international system of radiographic grading of vesico-ureteric reflux, along with a small diverticulum measuring approximately 9×8 mm in the right posterior wall of the urinary bladder close to the vesico-ureteric junction, with an opening of the right ureter into the diverticulum. The left kidney showed mild compensatory hypertrophy measuring 12 cm.

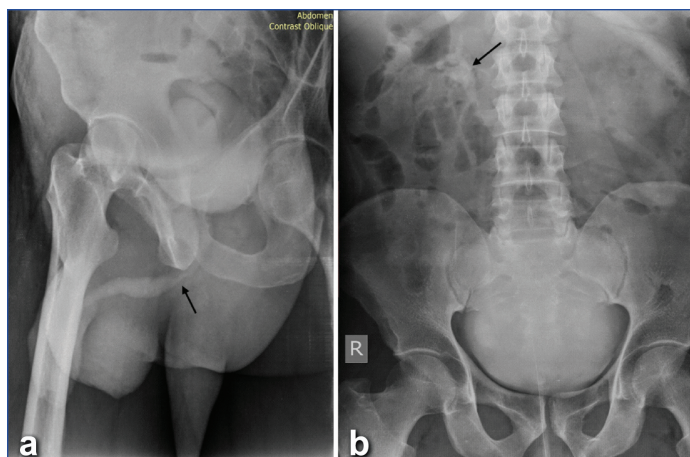
A diagnostic cystoscopy [Table/Fig-3] performed under general anaesthesia confirmed the presence of a diverticulum with the opening of the right ureter into the diverticulum. There were no signs of cystitis during cystoscopy. Since the patient was unwilling to undergo surgery or further investigations, it was decided to manage the patient conservatively with antibiotics, anti-spasmodics, and follow-up unless complications due to voiding dysfunction arise, necessitating surgical intervention.



**[Table/Fig-2]:** a-d) Computed Tomography (CT) images immediately after micturating cystourethrography shows small diverticula in right posterior wall of urinary bladder (white arrows in 'a-c') with right ureter (red arrow in 'a,c') inserting into it. Small sized right kidney with grade 2 vesicoureteric reflux and cortical scarring noted on right-side (yellow arrow in 'd').



**[Table/Fig-3]:** Cystoscopy image showing hutch diverticulum (black arrow).



**[Table/Fig-1]:** a,b) Micturating cystourethrography images showing normal urethra (black arrow in 'a') and grade 2 vesicoureteric reflux on right-side (black arrow in 'b').

## DISCUSSION

Urinary bladder diverticulum is a rare condition caused by the failure of detrusor muscle development at or near the ureteral orifice, leading to diverticula formed by the herniation of bladder wall mucosa through a weak point [1,2]. Diagnosis is considered in the absence of neurogenic bladder and posterior urethral valves. Congenital diverticula are uncommon in children and even rarer in adults [1,2]. In this case, the cause of the diverticulum was congenital since there was no evidence of bladder outlet obstruction. They are mostly unilateral and very rarely bilateral [1-3].

Some of them have the ureteric orifice incorporated in them, as in this case, which is even rarer. The incorporation of the ureteric orifice into the Hutch diverticulum is rare, with only a few reported cases. In a study by Rawat J et al., out of nine cases with bladder diverticula, two had peri-ureteral openings like the present case [4]. In a case report by Metin T, the ureteric orifice opened into the bladder diverticulum, as in presently discussed case [5].

Most diverticula are asymptomatic. A diverticulum associated with the ureter alters the normal anatomical insertion of the ureter into the bladder. Most bladder diverticula may be incidentally diagnosed during the evaluation of patients for recurrent urinary tract infections, incontinence, or urine retention [4,5]. Some may rarely develop complications like secondary calculi. Symptoms are more pronounced in patients with a large diverticulum, whereas cases with a small diverticulum may remain undiagnosed, as in our case. Vesico-ureteric reflux is caused by an incompetent vesico-ureteric junction due to disruption of the normal oblique insertion of the ureter at the vesico-ureteric junction [3,4]. Long-standing vesico-ureteric reflux with resultant medical renal disease can also be a presentation of Hutch diverticulum. In the present case, due to vesico-ureteric reflux, there was cortical scarring and a small-sized kidney.

Given the low prevalence, there is no gold standard treatment for this congenital disease. Treatment will depend on the symptoms and complications that the diverticulum generates or brings on. Both conservative and surgical reconstruction are reported in the literature. Diverticulectomy is necessary whenever the patient suffers from recurrent UTIs, bladder stones, complicated vesicoureteral reflux, voiding dysfunction, and urinary retention [6].

## REFERENCES

- [1] Palmero Martí JL, Ramirez Backhaus M, Alvarez Barrera A, Amoros Torres A, Benedicto Redon A. Hutch bladder diverticula: A very uncommon entity in adults. Arch Esp Urol. 2012;65(6):636-39. English, Spanish. PMID: 22832648.
- [2] Gkalonaki I, Anastasakis M, Panteli C, Patoulias I. Hutch diverticulum: From embryology to clinical practice. Folia Med Cracov. 2022;62(4):57-62.
- [3] Chawla S, Bhatt S, Tandon A, Meena G, Dangwal S. Bilateral Hutch diverticula in an elderly male: Revelation of an unknown past. SA J Radiol. 2020;24(1):1963. Doi: 10.4102/sajr.v24i1.1963. PMID: 33391839; PMCID: PMC7756895.
- [4] Abou Zahr R, Chalhoub K, Ollaik F, Nohra J. Congenital bladder diverticulum in adults: A case report and review of the literature. Case Rep Urol. 2018;2018:9748926. Doi: 10.1155/2018/9748926. PMID: 29568661; PMCID: PMC5820673.
- [5] Metin T. Ureteral orifice opening into the bladder diverticulum in a boy: A case report. Ped Urol Case Rep. 2014;1(5):20-25.
- [6] Sengupta S, Basu S, Gupta S. An insight into the management of urinary bladder diverticulum: A retrospective observational study. Int J Adv Med. 2020;7(12):1820-24.

### PARTICULARS OF CONTRIBUTORS:

1. Junior Resident, Department of Radiodiagnosis, SRM Medical College Hospital and Research Centre, Kattankulathur, Chengalpattu, Tamil Nadu, India.
2. Professor and Head, Department of Radiodiagnosis, SRM Medical College Hospital and Research Centre, Kattankulathur, Chengalpattu, Tamil Nadu, India.
3. Junior Resident, Department of Radiodiagnosis, SRM Medical College Hospital and Research Centre, Kattankulathur, Chengalpattu, Tamil Nadu, India.
4. Junior Resident, Department of Radiodiagnosis, SRM Medical College Hospital and Research Centre, Kattankulathur, Chengalpattu, Tamil Nadu, India.

### NAME, ADDRESS, E-MAIL ID OF THE CORRESPONDING AUTHOR:

Senthil Kumar Aiyappan,  
Professor and Head, Department of Radiodiagnosis, SRM Medical College Hospital and Research Centre, Kattankulathur, Chengalpattu-603203, Tamil Nadu, India.  
E-mail: asenthilkumarpgi@gmail.com

### PLAGIARISM CHECKING METHODS: [Jain H et al.]

- Plagiarism X-checker: Dec 19, 2023
- Manual Googling: Feb 07, 2024
- iThenticate Software: Feb 21, 2024 (14%)

### ETYMOLOGY: Author Origin

EMENDATIONS: 6

### AUTHOR DECLARATION:

- Financial or Other Competing Interests: None
- Was informed consent obtained from the subjects involved in the study? Yes
- For any images presented appropriate consent has been obtained from the subjects. Yes

Date of Submission: Dec 19, 2023

Date of Peer Review: Feb 09, 2024

Date of Acceptance: Feb 23, 2024

Date of Publishing: Apr 01, 2024